



## PLATELET RICH PLASMA PREVENTS TITANIUM MESH EXPOSURE IN ALVEOLAR RIDGE AUGMENTATION WITH ANORGANIC BOVINE BONE



Journal:	<i>Journal of Clinical Periodontology</i>
Manuscript ID:	Draft
Manuscript Type:	Original Article Implant Dentistry
Date Submitted by the Author:	
Complete List of Authors:	Torres, Jesús; Universidad Rey Juan Carlos, Anatomía, Embriología y Estomatología Tamimi, Faleh; McGill University Alkhraisat, Mohammad Hamdan; Universidad Complutense de Madrid, Facultad de Farmacia Machón, Angel; Universidad Rey Juan Carlos, Anatomía, Embriología y Estomatología Linares, Rafael; Universidad Rey Juan Carlos, Anatomía, Embriología y Estomatología Prados-Frutos, Juan Carlos; Universidad Rey Juan Carlos, Anatomía, Embriología y Estomatología Lopez-Cabarcos, Enrique; Universidad Complutense de Madrid, Facultad de Farmacia
Topic:	Implantology
Keywords:	bone regeneration, PRP, Anorganic bovine bone
Main Methodology:	Clinical Trial



1  
2  
3  
4  
5  
6  
7  
8  
9  
10  
11  
12  
13  
14  
15  
16  
17  
18  
19  
20  
21  
22  
23  
24  
25  
26  
27  
28  
29  
30  
31  
32  
33  
34  
35  
36  
37  
38  
39  
40  
41  
42  
43  
44  
45  
46  
47  
48  
49  
50  
51  
52  
53  
54  
55  
56  
57  
58  
59  
60

## PLATELET RICH PLASMA PREVENTS TITANIUM MESH EXPOSURE IN ALVEOLAR RIDGE AUGMENTATION WITH ANORGANIC BOVINE BONE.

Jesús Torres<sup>1,2</sup>, Faleh Tamimi<sup>2,3</sup>, Mohammad Hamdan Alkhraisat<sup>4</sup>, Ángel Manchón<sup>1</sup>, Rafael Linares<sup>1</sup>, Juan Carlos Prados-Frutos<sup>1</sup>, Enrique López Cabarcos<sup>4</sup>

<sup>1</sup>Ciencias de la Salud III, Universidad Rey Juan Carlos, 28922, Alcorcón, Spain

<sup>2</sup>Private practice, Clinica Dental Alcalá, Madrid, Spain

<sup>3</sup>Faculty of Dentistry, McGill University, Montreal QC, Canada H3A2B2

<sup>4</sup>Faculty of Pharmacy, Universidad Complutense, 28040 Madrid, Spain

Corresponding author:

Jesús Torres García-Denche

Department of Health Sciences III; Faculty of Health Sciences, Rey Juan Carlos University, 28922 Alcorcón, Madrid, Spain.

Tel +34-913888606

e-mail: [jesus.torres@urjc.es](mailto:jesus.torres@urjc.es)

This work was supported by Ministry of Science and Technology (grant MAT2006-13646-C03-01), the postdoctoral fellow FECYT (F.T), the UCM Program for Research Groups, and the Spanish Agency of Internacional Cooperation (AECI/A011152/07).

## ABSTRACT

### Objective:

Bone augmentation with the titanium mesh (Ti-mesh) technique is susceptible to a large rate of complications such as morbidity of bone graft donor site, and mesh exposure to the oral cavity. The purpose of this study was to evaluate the efficacy of anorganic bovine bone (ABB) in alveolar bone augmentation with the Ti-mesh technique, as an alternative to autologous bone grafts. In addition, we investigated the effect of platelet rich plasma (PRP) in preventing mesh exposure, by applying it to cover the Ti-mesh.

**Materials and Methods:** The 30 patients recruited for this study underwent 43 alveolar bone augmentation with the Ti-mesh technique using in all of them ABB as graft material. In 15 patients the Ti-meshes were covered with PRP (PRP group) while in the other 15 the Ti-meshes were not (control group). After 6 months, patients were called for clinical, radiographic and histological evaluation, and implant placement surgery. A total of 97 implants were placed in the augmented bone and their evolution was followed up for a period of 24 months.

### Results:

Significant differences were found between the two study groups in terms of complications and bone formation. In the control group 28.5% of the cases suffered from mesh exposure, while in the PRP group, no exposures were registered. Radiographic analysis revealed that bone augmentation was higher in the PRP group than in the control group. Interestingly, mesh exposure seemed to be a risk factor regarding graft resorption and failure.

Overall, 97.3% of implants placed in the control group and 100% of those placed in the PRP group were successful during the monitoring period.

We suggest that the positive effect of PRP on the Ti-mesh technique is due to its capacity to improve soft tissue healing, thereby protecting the mesh and graft material secured beneath the gingival tissues.

**Conclusions:** Alveolar bone augmentation using ABB alone in the Ti-mesh technique is sufficient for implant rehabilitation. Besides, covering the Ti-meshes with PRP was a determining factor for avoiding mesh exposure in this study. Titanium mesh exposure provoked significant bone loss, but in most cases it did not affect the subsequent placement of implants.

Key words: anorganic bovine bone, bone regeneration, platelet rich plasma, titanium mesh, exposure.

### Clinical Relevance

#### *Scientific rationale:*

Osteoconductive properties of ABB have been described in many bone augmentation procedures with good results, so it seemed reasonable to expect similar outcomes when applied in the Ti mesh technique. Although the use of PRP in bone regeneration is a moot question its effects over soft tissue seems to be clearer. In this study we compare both the efficacy of ABB alone and the effect of PRP over soft tissues in the titanium mesh technique.

1  
2  
3  
4  
5  
6  
7  
8  
9  
*Principal findings:*

ABB alone produces sufficient bone volume augmentation for implant rehabilitation and the use of PRP covering the titanium mesh can improve the soft tissue healing over the titanium mesh preventing its exposure.

10  
11  
12  
13  
14  
15  
16  
*Practical implications:*

ABB alone is an excellent graft material for the Ti mesh technique that achieves alveolar bone augmentation without the need of autologous graft. Moreover PRP can be an excellent tool for preventing mesh exposure in the Ti mesh technique.

17  
18  
19  
**Introduction**

Several techniques for alveolar bone augmentation have been described in order to give solution for inadequate alveolar bone volume, which often precludes the ideal placement of dental implants placement (Adell et al 1990, Simion et al 1994, Buser et al 2000, Cordaro et al 2002, Rochietta et al 2008). Onlay grafts and guide bone regeneration (GBR) are widely used for alveolar ridge augmentation prior or simultaneous implant placement. Clinical and histological data support the use of these approaches (van Steenberghe et al 1997, Keller et al 1999, Parma-Benfenati et al 1999). However, the success of GBR procedures seems to be highly technique-sensitive and therefore application to a wide community of operators and clinical settings remains unclear (Simion et al 1994a, Tinti et al 1996, Tinti & Benfenati 1998, Simion et al 2007, Rochietta et al 2008). On the other hand, onlay grafts implies the extraction of an autologous bone block that is often traumatic for the patient.

GBR presents several controversies concerning two aspects: the type of barrier and the type of graft used (Boyne et al 1985, von Arx et al 1996). Regarding the first issue, two principal barriers have been proposed: cell-occlusive membranes and Ti meshes. Cell-occlusive membranes showed very good results obtaining great quantity of regenerated bone, however they have demonstrated two major inconvenients, i) low stiffness for maintaining the contour of the regenerated sites and ii) a high risk of infection after wound dehiscence and barrier exposure (Simion et al 1994a, Simion et al 1994b, Simion et al 1994c). In GBR techniques, soft tissue closure over the augmented area plays an important role in preventing wound dehiscence and bacterial contamination of the exposed membrane. On the other hand GBR using Ti-mesh is a reliable technique with improved stiffness compared to cell occlusive membranes that obtaining predictable results in both width and vertical bone augmentation (Malchiodi et al 1998, Maiorana et al 2001, Artzi et al 2003, Profussaefs et al 2006, Corinaldesi et al 2007, Rocuzzo et al 2004, 2007, Pieri et al 2008).

Although, this technique is much more predictable in width bone augmentation, increase of vertical bone volume has been described even in severe cases, in a predictable way (Table 1).

Early studies advocated the use of autogenous bone in the augmented space beneath Ti meshes (Boyne et al 1985, von Arx et al 1996). Although the autologous bone is considered the gold standard bone substitute because of its intrinsic properties, its availability is restricted by the limited amount of intraoral grafts, the morbidity associated to second surgery at the donor site, and the high cost for bone harvesting

from extraoral sites. Therefore, alternative biomaterials have been developed to substitute autologous bone graft.

Among the available bone substitutes, anorganic bovine bone (ABB) have demonstrated to be the biomaterial with major long-term success reports in the literature used in alveolar bone augmentation techniques. Bio-Oss<sup>®</sup> (Geistlich Biomaterials; Wolhusen, Switzerland) is a biocompatible and osteoconductive ABB (Benezra *et al* 2002), that provides an ideal scaffold for new bone formation (Hammerle *et al* 1998, Piatelli *et al* 1999). It has been extensively used for alveolar bone augmentation (Valentini *et al* 2003, Wallace *et al* 2005) with high clinical success rates (Carmagnola *et al* 2003). Accordingly, previous studies have introduced the use of ABB to the Ti mesh technique, either alone, or combined with autologous bone (Maiorana *et al* 2001, Corinaldesi *et al* 2007, Pieri *et al* 2008) (Table 1).

Another major inconvenient of the Ti mesh technique concerns the high rate exposures. These exposures may facilitate graft infection or even loss (Table 1).

PRP is an autologous fibrin adhesive with high platelet concentration easily obtained from whole blood by centrifugation (Antoniades 1981; Marx *et al* 1998, Anitua 1999). Furthermore, PRP has a high concentration of angiogenic and mitogenic growth factors implicated in soft tissue healing, such as TGF (Wijesjo *et al* 1998), PDGF and EGF (Giannobile *et al.* 1996), and has been recently used to improve soft tissue healing in periodontology. PRP effects could enhance soft tissue healing over the Ti-mesh avoiding its exposure and prevents the derived complications.

In the present study, a clinical trial was performed to evaluate two aspects regarding the Ti mesh technique: i) to examine the outcome of ABB grafting alone, and ii) the benefit of covering the Ti-mesh with PRP, in order to improve soft tissue healing and prevent exposure. The results were obtained by means of clinical investigation, radiographs and histological analysis.

Table 1. Summary of clinical studies reporting the amount bone gained and complications rate using the Ti-mesh technique

Pts/BAP (n/n)	Type of Graft (%)	ABW (mm)	ABH (mm)	ME (%)	Impl (n)	Survival (%)	Success (%)	References
20/20	AB (100)	ID	ID	50	28	ID	ID	Von Arx <i>et al</i> 1996
25/25	AB (100)	5.65	ID	0	120	ID	100	Malchiodi <i>et al</i> 1998
23/23	AB (100) *	ID	5	17.3	ID	ID	ID	Rocuzzo <i>et al</i> 2004
18/18	AB (100) *	ID	4.8	22.2	37	100	100	Rocuzzo <i>et al</i> 2007
14/23	AB/ABB (50/50)	ID	ID	14.2	59	98.3	ID	Maiorana <i>et al</i> 2001
16/19	AB/ABB (70/30)	4.16	3.71	5.3	44	100	100	Pieri <i>et al</i> 2008
12/12	AB/ABB (70/30)	ID	ID	0	35	100	100	Corinaldesi <i>et al</i> 2007
7/7	AB/ABB (ID)	3.71	2.86	57	ID	ID	ID	Profusaefs & Lozana 2004
10/10	ABB (100)	ID	5.2	20	20	100	ID	Artzi <i>et al</i> 2003

Pts: patients; BAP: bone augmentation procedures; ABH: average bone height gained; ABW: Average bone width gained; ME: mesh exposure; Impl: implants placed; ID: Insufficient data; \*: block grafts.

## Patient and methods

### Patients

Before commencing this study, approval was obtained from the ethical committee for clinical trials of the “Hospital San Carlos” (Madrid, Spain), to carry out a pilot clinical study in the dental clinic “Clinica Dental Alcala” (Madrid, Spain). Patients were enrolled in the study on the basis of having insufficient bone height (< 7 mm), width (< 3 mm) or both, in either maxilla or mandible (Figure 1).

Patients who need contemporary sinus floor augmentation or nasal floor augmentation were included, while smokers (>10 cigarets per day) and patients with severe systemic disease (ASA (III or IV) – American Society of Anesthesiology) were excluded. Informed written consent to participate in this study was obtained from all patients after explaining the objectives and protocol of the study, and possible side effects.

During the study period (from May 2003 to September 2008) 209 patients attended the dental office demanding implant treatment. Among these patients, 30 were recruited for this randomized controlled clinical trial. The study group constituted by 17 females and 13 males with age range between 48 and 76 years old.

There was heterogeneity in the systemic diseases present in some of the selected patients, such as diabetes, heart failure and osteoporosis; however, none of these conditions are known to jeopardize implant’s success (Mombelli *et al* 2006).

Figure 1. Summarize the average residual bone height and width, the site of intervention and type of GBR procedure performed on the patients included in the study. Most of the procedures involved situations with extended tooth gaps and distal extension, and combined vertical and horizontal bone augmentations.

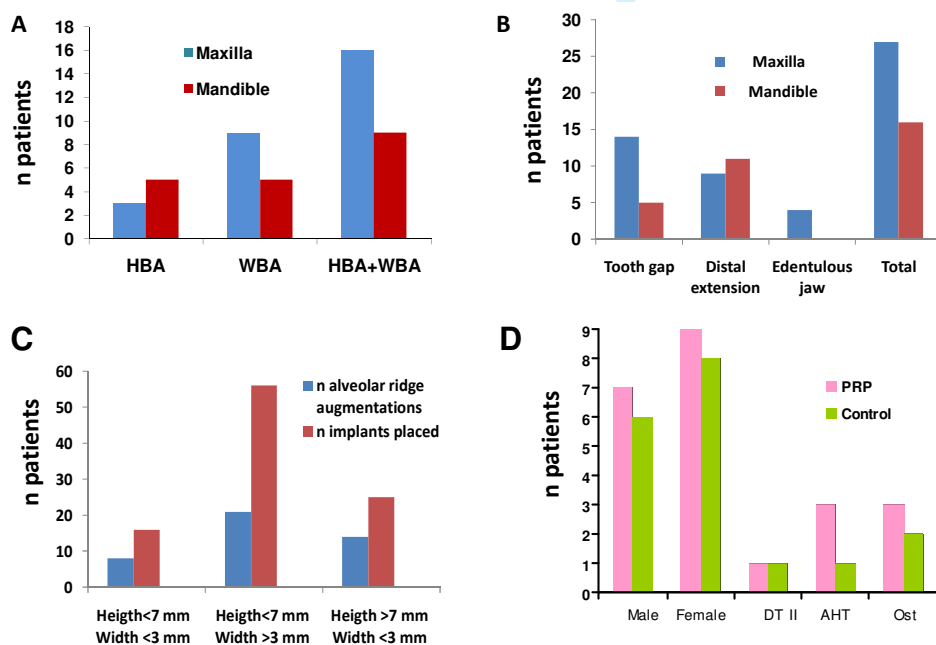


Fig 1. Distribution of: patients as a function of bone augmentation procedure (A); patients as function of treatment site (B); treatment procedures as function of residual bone graft size



1  
2  
3 (C); and patients by medical situation and treatment group (D). HBA: height bone  
4 augmentation; WBA: width bone augmentation. DT II: Type II diabetes; ATH: arterial  
5 hypertension; Ost: osteoporosis.  
6  
7

### 8 9 ***Randomization***

10  
11 Patients included in the clinical trial were randomly allocated by a blinded assistant in  
12 two groups, the first was to be treated with PRP covering of the Ti-mesh (PRP group),  
13 while the second one did not receive the PRP treatment (control group). Allocation of  
14 participants to intervention groups in a truly unpredictable, randomized sequence was  
15 performed by computerized random number generated using GraphPadQuickCalc  
16 software (GraphPad Software Inc., La Jolla, CA), including the concealment of the  
17 allocation schedule until the assignment was made. Subject numbers were assigned at  
18 the baseline examination in consecutive order by the principal investigator. The sample  
19 size used has been usual in previous studies for this type of clinical evaluation (Table  
20 1). The presence of systemic disorders was registered and its distribution was balanced  
21 among the two treatment groups (Figure 1D).  
22  
23  
24

### 25 26 ***Blinding***

27  
28 The surgeon was blinded to the graft covering material applied to each patient before  
29 graft implantation. An assistant handled the PRP or nothing once the Ti-meshes were  
30 placed.  
31  
32

### 33 34 ***Platelet rich plasma***

35  
36 PRP was prepared according to the Anitua's method<sup>15</sup> (Anitua 1999). Blood was  
37 collected from all patients 30 minutes before starting the surgery to ensure the blinding  
38 of the surgeon. In the PRP group, between 10-20 ml of blood was withdrawn via venous  
39 aspiration into 4.5 ml test tubes and mixed with a 3.8 % sodium citrate solution at a  
40 ratio 5/1 (v/v) achieving anticoagulation through calcium binding. The blood was then  
41 centrifuged with a Bti<sup>®</sup> PRGF System II centrifuge (Bti Biotechnology Institute S.L,  
42 Vitoria, Spain) into three basic components: red blood cells (RBCs), PRP, and platelet  
43 poor plasma (PPP) (Figure 2A). Because of the different densities of the components,  
44 the RBC layer forms at the bottom of the tube, the PRP layer in the middle, and the PPP  
45 layer at the top. A pipette (Gilson Inc., Middleton, WI) was used to separate the layers,  
46 from the less dense to the denser. Therefore PPP was separated first (about 2.25 ml  
47 followed by PRP (about 0.9 ml), leaving as residual the RBCs layer (about 2.25 ml)  
48 (Figure 2B).  
49  
50  
51

### 52 53 ***Surgical protocol***

54  
55 An alveolar ridge augmentation was performed in all patients following the method  
56 described by Boyne et al (1985) and Von Arx et al (1996).  
57

58  
59 Under local anesthesia a mid-crestal with divergent buccal incisions was performed to  
60 allow elevate two mucoperiosteal flaps to the buccal and palatal aspects. Perforations  
into the marrow space were produced. In all patients ABB particles were adapted to the

1  
2  
3 deficient ridge and a Ti-mesh that was individually trimmed previously was placed over  
4 the grafts and fixed with micro-screws. Subsequently PRP was used as a membrane  
5 covering the Ti-meshes in the PRP group, while nothing was added to cover the Ti-  
6 mesh in the control group (Figure 3). Then released periosteal incisions were made and  
7 a tension free, tight wound closure was accomplished. Postoperatively, antibiotics, anti-  
8 inflammatory and antiseptics were prescribed, and sutures were removed 1 week after  
9 surgery. Patients were instructed not to wear their prosthesis for 6 months after surgery  
10 to avoid transmucosal pressure on the augmented area. All patients were required to  
11 follow a soft diet. A healing time of 6 months was allowed before implant placement  
12 (Osseotite, Biomet 3i Inc, Palmbeach, FL). A representative case with this  
13 reconstructive method is presented (Fig 3).  
14  
15  
16

### 17 *Radiographical analysis*

18  
19  
20 Radiographs (orthopantomography) and computed tomographies (CT) of the treated  
21 sites were taken before treatment, and six months postoperatively. The bone volume  
22 was quantified in both PRP and control groups using the SIMPlant 7.0 software  
23 (Columbia Scientific, Columbia, MD). Three selected zones in each alveolar ridge  
24 augmentation were chosen for standardized evaluation. Differences between  
25 preoperative and postoperative bone height and width were measure to assure the  
26 alveolar bone augmentation obtained. (Pieri et al 2008). Implant osteintegration and  
27 success was assessed by radiographical analysis of the implanted sites 6 months after  
28 their placement.  
29  
30  
31  
32

### 33 *Histological analysis*

34  
35 The histological analysis was performed in 2 patients of each group. After a healing  
36 period of 6 months, these patients were called for implant placement and biopsies were  
37 retrieved from the treated sites using a trephine burr ( $\varnothing = 3.0 \text{ mm} \times 10.0 \text{ mm}$  in length).  
38 Subsequently the biopsies were fixed in a 10% formaldehyde (pH 7.4) and stored at  
39  $4^{\circ}\text{C}$ . After dehydration in ascending series of alcohol (60 to 100 %), biopsies were  
40 embedded in 2-hidroxy-ethyl-methacrylate (Technovit, Leica Microsystems GMBH,  
41 Wetzlar), then polymerized into ready-to-cut sample blocks.  
42  
43  
44

45 A saw microtome (1200 Leica, Leica Microsystems GmbH, Wetzlar, Germany) was used to  
46 cut  $15 \mu\text{m}$  thick histological sections from the blocks. Afterwards, surface staining was  
47 performed with basic fuchsine and methylene blue (Donath & Breuner 1982). The  
48 histological evaluation of bone neof ormation was carried out by means of optical  
49 microscopy.  
50

### 51 *Statistical analysis*

52  
53 The distribution of patients' systemic conditions (diabetes, smoking, etc...) among  
54 clinical treatments' groups was assessed using the chi-square test, in order to evaluate  
55 comparability between groups. Moreover two-way ANOVA tests, in the univariate  
56 analysis were used to find any association between patients' treatment, the Ti-mesh  
57 exposure, and treatment success. A statistical software package (SPSS 17.0 Chicago,  
58 IL) was used for the statistical analysis.  
59  
60



## Results

The bone augmentation, and implant placement procedures performed in this study are summarize in Table 2.

Mostly, healing was uneventful in all patients since none of them complained of significant pain and no signs or symptoms of infection were reported.

Successful alveolar ridge augmentations allowed the installation of one to three rough-surfaced implants per site (Osseotite, Biomet 3i Inc, Palmbeach, FL) with diameters of 3.3-4.0 mm and lengths of 10.0-13.0 mm.

During the 24 month follow up period, one case of graft failure and another of implant failure were registered in the control group, while the PRP group presented no complications (see Table 2 and 3). Moreover, the amount of bone height and width gained was higher in patients treated with PRP (Table 2).

Successful implants were uncovered for fixed prosthetic rehabilitation and no implant complications were registered beyond this point.

*Table 2. Distribution of patients, alveolar ridge augmentations, complications and implants by Ti-mesh covering*

Treatment group	n patients/ n grafts	Graft complications (%)		ABH (mm)	ABW (mm)	ABHL	ABWL	Impl <sup>failed</sup> / Impl <sup>total</sup>	Impl Survival (%)
		Mesh exposure	Failure						
PRP	15/22	0.0**	0.0	3.5±0.7**	4.1±0.6**	0.5±0.6	NRA	0/51	100
Control <sup>†</sup>	15/21	28.5	4.0	3.1±0.8	3.7±0.6	0.7±0.6	NRA	1/46	97.3
Total	30/43	14.0	2.3	[2.3±0.2]*	[3.1±0.2]*	[1.1±0.9]*	[0.6±0.5]*	[0/12]	[100]
				3.3±0.2	3.9±0.2			3/97	98.6

ABH: Average bone height gained; ABW: Average bone width gained; Impl: Implants placed; ABHL: Average bone height loss; ABWL: Average bone width loss; NRA: No radiographically appreciated; <sup>†</sup> patient who loss complete graft was excluded from statistical analysis. [ ] Values for exposed meshes. \*\*Significant differences between PRP and control groups ( $p<0.05$ ). \* Significant differences between exposed and non exposed meshes ( $p<0.05$ ).

### *Histological observations*

Histological analysis of the regenerated sites revealed the presence of mineralized newly formed bone growing beneath the Ti-mesh, surrounding the un-resorbed ABB granules (Figure 5). Its is important to notice the absence of fibrous tissue and the complete enclosure of ABB granules within the new bone. These observations confirm the validity of ABB in regenerating bone beneath Ti-meshes for GBR.

### *Surgical complications*

The main complication registered during the study was Ti-mesh exposure (Figure 6). This condition was observed in 6 cases, all belonging to the control group (Table 3). In 5 of these cases, the exposure area were small ( $\leq 10 \text{ mm}^2$ ) while in one patient a large exposure area took place ( $>10 \text{ mm}^2$ ). Ti-mesh exposure proved to be a risk factor

regarding partial resorption or complete loss of the grafts (Table 2). Interestingly, no Ti-mesh exposures, or implant failures were observed in the PRP group.

*Table 3. Detail of patients with Ti-mesh exposure*

Gender	Age (years)	Preoperative Bone Height & Width (mm)		Ti-mesh exposure (mm <sup>2</sup> )	Postoperative Bone Height & Width (mm)		Implants' Position
		Pre-BH	Pre-BW		Post-BH	Post-BW	
M	55	10	3	<10	10	5.5	13,23
F	42	9	2.5	<10	11.5	5.5	24,26,27
F	62	8	6	<10	10	6	46,47
F	58	9	4	<10	11.5	6.5	35,37
F*	51	5	7	<10	5	7	46*
M <sup>†</sup>	69	10	3	>10 <sup>†</sup>	10	5.5	23,24

\* In this patient infection and total graft loss occurred, but still a 6.0 mm long x 5.0 mm wide implant was placed leaving the upper machined part of the implant over the bone residual bone crest.

<sup>†</sup> Large exposure area of the Ti-mesh, but it did not prevented implant placement

### *Survival of grafts*

Pre and postoperative bone volume were measure and compared between groups, and also between patients with Ti-mesh exposure versus no Ti-mesh exposed patients for statistical analysis. Vertical bone volume augmentation was defined as the distance between the top of the Ti-mesh and the highest point of the crest postoperatively, while the horizontal bone volume augmentation was measure by the distance between the most buccal point of the residual bone and the Ti-mesh. The radio-opacity of ABB made easy the difference between the residual bone and the new regenerated bone (Figure 3).

Evaluation of graft loss was achieved by measuring the black space between the mesh and the new regenerated bone. Although a higher incidence of graft loss occurred in the control group, no statistical differences were observed between the two groups. However, Ti-mesh exposure provoked significant increase of graft loss in the control patients (Table 2).

Graft survival at the secondary surgery was sufficient to allow implant placement in all the patients included in the study except one in which an implant 5.0mm x6.0 mm were placed because a completely loss of the graft. However, we found that in five cases partial loss of bone graft occurred probably because of Ti-mesh exposure (Table 2).

All patients with PRP treatment did not showed Ti-mesh exposure while patients with no PRP treatment showed a significantly higher incidence (28%) of Ti-mesh exposures (Table 2 and 3). Also vertical and horizontal bone volume augmentation, were significantly slightly higher in the PRP group ( $p<0.05$ ).

### *Implant survival rates*

1  
2  
3 Implant survival was defined as the percentage of implants remaining in situ during the  
4 entire observation period. In this study over 97 implants were placed, 95 remain in situ,  
5 and 2 failed in the control group, which gave a 97.5% implant survival rate (Table 2).  
6 We did not found differences between the PRP and control groups in terms of implant  
7 survival, and mesh exposure did not affect implant success as well.  
8  
9

## 10 Discussion

11  
12 Early studies on the Ti-mesh technique based on the use of autologous bone achieved  
13 promising results in augmented bone volume and implant survival (Table 1). However  
14 the use of autologous bone is restricted by its associated of morbidity, surgical cost, and  
15 limited amount of intraoral grafts.  
16  
17

18  
19 Recent studies (Maiorana et al 2001; Profussefs & Lozana 2006; and Pieri et al 2008)  
20 proposed the combination of autologous bone with ABB in order to reduce the need of  
21 bone harvesting from patients. These procedures achieved positive results that  
22 encouraged consequent assays evaluating the potential of using ABB alone in Ti mesh  
23 vertical bone augmentations (Table 1).  
24  
25

26 In this study ABB alone achieved similar results to those previously described for  
27 autologous grafts Ti mesh GBR. Our results suggested that vertical and horizontal bone  
28 augmentation with Ti-mesh using ABB alone as graft material is predictable and has a  
29 low incidence of major complications. These results have major implications, thus by  
30 eliminating the need for autologous grafts in GBR procedures a larger scope of patients  
31 may be treated. Moreover, unlike autologous grafts, ABB grafts proved to be the  
32 dimensionally stable during the two year follow up period. Probably due the  
33 combination of biocompatibility, osteoconductivity, and low resorption properties of  
34 ABB in vivo (Schlegel et al, 2003, Zitmann et al 2001).  
35  
36

37  
38 Ti-mesh exposure has been correlated to subsequent complications such as graft  
39 resorption and loss, often impairing implant treatment (Von Arx, 1996). These facts  
40 were confirmed in this study, since graft resorption and loss occurred only in cases were  
41 exposure of the Ti mesh took place.  
42

43 The patients of the control group suffered from a rate of complications, similar to that  
44 reported in the previous literature for GBR with autologous graft and Ti meshes (Table  
45 1 and 2). On the other hand, the incidence of Ti mesh exposure was completely  
46 eradicated in the PRP treated group (Table 2).  
47

48  
49 It was observed that soft tissue healing was better when PRP was applied over the Ti-  
50 mesh compared to controls without PRP coverage. This was likely to translated into an  
51 improved gingival biotype and subsequent important resistance to Ti-mesh exposure.  
52

53  
54 There is a large controversy regarding the usefulness of PRP in bone regeneration  
55 procedures (Torres et al 2009). Many studies have shown that PRP is unable to  
56 influence bone growth in cavities and defects. However, most of the dental literature has  
57 been focused on evaluating its effect on hard tissues, ignoring potential benefits on  
58 surrounding soft tissues.  
59

60  
PRP may enhance soft tissue healing by concentrating large amounts of fibrin and  
growth factors secreted by platelets, that increases both angiogenesis and fibroblast cell

1  
2  
3 differentiation (Tamimi et al 2007). PRP increases early wound strength, by reducing  
4 the inflammatory phase of wound healing allowing early deposition of collagen,  
5 glycosaminoglycan and fibronectin. Moreover, PRP has also been found to decrease in  
6 patient morbidity and pain (Bathusky & Wang 2008).  
7  
8  
9

10 Interestingly, gingival healing seemed to have an effect on the underlying bone  
11 formation. Bone grafts in the control group experience resorption beneath the Ti-mesh,  
12 while in the PRP group the amount of augmented bone was higher and no graft  
13 resorption was observed. However, we believe this phenomenon occurs mainly due to  
14 soft tissue protection rather than by direct effect on bone formation.  
15  
16

## 17 Conclusion

18  
19  
20 The results of the present study demonstrated that ABB alone may be used as graft  
21 material in the Ti-mesh technique with predictable results for localized ridge  
22 augmentation in humans. Moreover, applying PRP over the Ti mesh, achieved a major  
23 reduction in complications such as graft failure, graft resorption and mesh exposure.  
24  
25

## 26 Acknowledgments

27 Authors acknowledge Mrs. Ascension Marin and the staff of “Clinica Dental Alcalá”  
28 for their help and support of this study.  
29  
30

## 31 References

32  
33  
34 Adell, R., Lekholm, U., Gröndahl, K., Brånemark, P.I., Lindström, J. & Jacobsson, M.  
35 (1990). Reconstruction of severely resorbed edentulous maxillae using osseointegrated  
36 fixtures in immediate autogenous bone grafts. *International Journal of Oral and*  
37 *Maxillofacial Implants* **5**,233-246.  
38

39  
40 Anitua, E. (1999) Plasma rich in growth factors: Preliminary results of use in the  
41 preparation of future sites for implants. *International Journal of Oral and Maxillofacial*  
42 *Implants* **14**, 429-535  
43

44  
45 Antonaides, H.N. (1981) Human platelet -derived growth factor (PDGF): Purification of  
46 PDGF-I and PDGF-II and separation of their reduced subunits. *Proceedings of the*  
47 *National Academy of Sciences* **78**, 7314-7317  
48

49  
50 Artzi, Z., Dayan, D., Alpern, Y. & Nemcovsky C.E. (2003) Vertical ridge augmentation  
51 using xenogenic material supported by a configured titanium mesh: clinicohistopathologic and  
52 histochemical study. *International Journal Oral Maxillofacial Implants* **18**,440-446  
53

54  
55 Bashutski JD & Wang HL (2008) Role of platelet-rich plasma in soft tissue root-  
56 coverage procedures: a review. *Quintessence International* **39**,473-83.  
57

58  
59 Carmagnola, D., Adriaens, P. & Berglundh, T. (2003) Healing of human extraction  
60 sockets filled with Bio-Oss. *Clinical Oral Implants Research* **14**, 137-143

1  
2  
3 Boyne P J., Cole M. D., Stringer D. & Shafiqat J. P. (1985) A technique for osseous  
4 restoration of deficient edentulous maxillary ridges. *Journal Oral Maxillofacial Surgery*  
5 **43**, 87-91.  
6  
7

8  
9 Buser, D., Dula, K., Hess, D., Hirt, H.P. & Belser, U.C. (1999). Localized ridge  
10 augmentation with autografts and barrier membranes. *Periodontology 2000* **17**,22-35  
11  
12

13 Cordaro, L., Amadé, D.S., Cordaro, M. (2002) Clinical results of alveolar ridge  
14 augmentation with mandibular block bone grafts in partially edentulous patients prior to  
15 implant placement. *Clinical Oral Implants Research* **13**,103-111.  
16

17 Corinaldesi G., Pieri F., Marchetti C., Fini M., Aldini N. N. & Giardino R. (2007)  
18 Histologic and histomorphometric evaluation of alveolar ridge augmentation using bone  
19 grafts and titanium micromesh in humans. *Journal of Periodontology* **78**,1477-1484.  
20  
21

22  
23 Donath, K. & Breuner, G. (1982) A method for the study of undecalcified bones and  
24 teeth with attached soft tissues. The Säge-Schliff (sawing and grinding) technique.  
25 *Journal of Oral Pathology* **11**, 318-26  
26  
27

28  
29 Giannobile, W.V., Hernandez, R.A., Finkelman, R.D., Ryan, S., Kiritsy, C.P.,  
30 D'Andrea, M. & Lynch, S.E. (1996) Comparative effects of platelet-derived growth  
31 factor-BB and insulin-like growth factor-I, individually and in combination, on  
32 periodontal regeneration in *Macaca fascicularis*. *Journal of Periodontal Research* **31**,  
33 301-312  
34

35 Hämerle, C.H., Chiantella, G.C., Karring, T, & Lang, N.P. (1998) The effect of a  
36 deproteinized bovine bone material on bone regeneration around titanium dental  
37 implants. *Clinical Oral Implants Research* **9**, 151-162  
38

39 Keller, E.E., Tolman, D.E. & Eckert, S. (1999) Surgical-prosthetic reconstruction of  
40 advanced maxillary bone compromise with autogenous onlay block bone grafts and  
41 osseointegrated endosseous implants: a 12-year study of 32 consecutive patients.  
42 *International Journal of Oral and Maxillofacial Implants* **14**,197-209.  
43  
44

45 Maiorana C., Santoro F., Rabagliati M.& Salina S. (2001) Evaluation of the use of iliac  
46 cancellous bone and anorganic bovine bone in the reconstruction of the atrophic maxilla  
47 with titanium mesh: a clinical and histologic investigation. *International Journal Oral*  
48 *Maxillofacial Implants* **16**,427-432.  
49  
50

51 Malchiodi L., Scarano A., Quaranta M. & Piattelli A. (1998) Rigid fixation by means  
52 of titanium mesh in edentulous ridge expansion for horizontal ridge augmentation in the  
53 maxilla. *International Journal Oral Maxillofacial Implants* **13**,701-705.  
54  
55

56 Mombelli, A. & Cionca, N. Systemic diseases affecting osseointegration therapy.  
57 (2006) *Clinical Oral Implants Research* **17**, 97-103.  
58  
59  
60



1  
2  
3 Parma-Benfenati, S., Tinti, C., Albrektsson, T. & Johansson, C. (1999) Histologic  
4 evaluation of guided vertical ridge augmentation around implants in humans.  
5 *International Journal Periodontics and Restorative Dentistry* **19**, 424-437.  
6

7  
8 Piattelli, M., Favero, G.A., Scarano, A., Orsini, G. & Piattelli, A. (1999) Bone reactions  
9 to anorganic bovine bone (Bio-Oss) used in sinus augmentation procedures: a histologic  
10 long-term report of 20 cases in humans. *International Journal of Oral and Maxillofacial*  
11 *Implants* **14**, 835-840  
12

13  
14 Pieri F., Corinaldesi G., Fini M, Aldini N. N., Giardino R. & Marchetti C. (2008)  
15 Alveolar ridge augmentation with titanium mesh and a combination of autogenous bone  
16 and anorganic bovine bone: a 2-year prospective study. *Journal of Periodontology*  
17 **79**,2093-2103.  
18

19  
20 Proussaefs P. & Lozada J. (2006) Use of titanium mesh for staged localized alveolar  
21 ridge augmentation: clinical and histologic-histomorphometric evaluation. *Journal of*  
22 *Oral Implantology* **32**,237-247.  
23

24  
25 Proussaefs P., Lozada J., Kleinman A., Rohrer M. D. & McMillan P J. (2003) The use  
26 of titanium mesh in conjunction with autogenous bone graft and inorganic bovine bone  
27 mineral (bio-oss) for localized alveolar ridge augmentation: a human study.  
28 *International Journal Periodontics and Restorative Dentistry* **23**,185-195.  
29

30  
31 Roccuzzo M., Ramieri G., Spada M. C., Bianchi S. D. & Berrone S. (2004). Vertical  
32 alveolar ridge augmentation by means of a titanium mesh and autogenous bone grafts.  
33 *Clinical Oral Implants Research* **15**,73-81  
34

35  
36 Roccuzzo, M., Ramieri, G., Bunino, M. & Berrone S. (2007) Autogenous bone graft  
37 alone or associated with titanium mesh for vertical alveolar ridge augmentation: a  
38 controlled clinical trial. *Clinical Oral Implants Research*. **18**,286-294  
39

40  
41 Rocchietta, I., Fontana, F. & Simion, M. (2008) Clinical outcomes of vertical bone  
42 augmentation to enable dental implant placement: a systematic review. *Journal of*  
43 *Clinical Periodontology*. **35**, 203-215  
44

45  
46 Rosen, B.V., Hobbs, L.W. & Spector, M. (2002) The ultrastructure of anorganic  
47 bovine bone and selected synthetic hydroxiapatites used as bone graft substitute  
48 materials. *Biomaterials* **23**, 921-928  
49

50  
51 Schlegel KA, Fichtner G, Schultze-Mosgau S & Wiltfang J (2003) Histologic findings  
52 in sinus augmentation with autogenous bone chips versus a bovine bone substitute.  
53 *International Journal of Oral and Maxillofacial Implants* **18**,53-8.  
54

55  
56 Simion, M., Trisi, P. & Piattelli, A. (1994a) Vertical ridge augmentation using a  
57 membrane technique associated with osseointegrated implants. *International Journal of*  
58 *Periodontics and Restorative Dentistry* **14**, 496-511.  
59

60  
Simion, M., Trisi, P., Maglione, M. & Piattelli, A. (1994b) A preliminary report on a  
method for studying the permeability of expanded polytetrafluoroethylene membrane to



1  
2  
3 bacteria in vitro: a scanning electron microscopic and histological study. *Journal of*  
4 *Periodontology* **65**,755-761.  
5  
6

7 Simion, M., Baldoni, M., Rossi, P. & Zaffe, D. (1994c) A comparative study of the  
8 effectiveness of e-PTFE membranes with and without early exposure during the healing  
9 period. *International Journal of Periodontics and Restorative Dentistry* **14**,166-180.  
10

11 Simion, M., Fontana, F., Rasperini, G. & Maiorana, C. (2007) Vertical ridge  
12 augmentation by expanded-polytetrafluoroethylene membrane and a combination of  
13 intraoral autogenous bone graft and deproteinized anorganic bovine bone (Bio Oss).  
14 *Clinical Oral Implants Research* **18**,620-629.  
15

16 Tinti, C., Parma-Benfenati, S. & Polizzi, G. (1996) Vertical ridge augmentation: what is  
17 the limit? *International Journal of Periodontics and Restorative Dentistry* **16**,220-229.  
18

19 Tinti, C. & Parma-Benfenati, S. (1998) Vertical ridge augmentation: surgical protocol  
20 and retrospective evaluation of 48 consecutively inserted implants. *International*  
21 *Journal of Periodontics and Restorative Dentistry* **18**,434-443.  
22

23 Tamimi, F.M., Montalvo, S., Tresguerres, I. & Blanco Jerez, L. (2007) A comparative  
24 study of 2 methods for obtaining platelet-rich plasma. *Journal of Oral and*  
25 *Maxillofacial Surgery* **65**, 1084-1093.  
26  
27

28  
29  
30 Torres, J., Tamimi, F., Martinez, P.P., Alkhraisat, M.H., Linares, R., Hernández, G.,  
31 Torres-Macho, J. & López-Cabarcos, E. (2009) Effect of platelet-rich plasma on sinus  
32 lifting: a randomized-controlled clinical trial. *Journal of Clinical Periodontology* **36**,  
33 677-687.  
34

35  
36 Valentini, P. & Abensur, D.J. (2003) Maxillary sinus grafting with anorganic bovine  
37 bone: a clinical report of long-term results. . *International Journal of Oral and*  
38 *Maxillofacial Implants* **18**, 556-560.  
39  
40

41  
42 Von Arx T., Hardt N. & Wallkamm B. (1996) The TIME technique: a new method for  
43 localized alveolar ridge augmentation prior to placement of dental  
44 implants. *International Journal Oral Maxillofacial Implants* **11**,387-394.  
45  
46

47  
48 Van Steenberghe, D., Naert, I., Bossuyt, M., De Mars, G., Calberson, L., Ghyselen, J. &  
49 Brånemark, P.I. (1997). The rehabilitation of the severely resorbed maxilla by  
50 simultaneous placement of autogenous bone grafts and implants: a 10-year evaluation.  
51 *Clinical Oral Investigations* **1**,102-108  
52

53  
54 Wallace, S.S., Froum, S.J., Cho, S.C., Elian, N., Monteiro, D., Kim, B.S. & Tarnow,  
55 D.P. (2005) Sinus augmentation utilizing anorganic bovine bone (Bio-Oss) with  
56 absorbable and nonabsorbable membranes placed over the lateral window:  
57 histomorphometric and clinical analyses. *International Journal of Periodontics*  
58 *Restorative Dentistry* **25**, 551-559  
59  
60

1  
2  
3 Wikesjö, U.M., Razi, S.S., Sigurdsson, T.J., Tatakis, D.N., Lee, M.B., Ongpipattanakul,  
4 B., Nguyen, T. & Hardwick, R. (1998) Periodontal repair in dogs: effect of recombinant  
5 human transforming growth factor-beta1 on guided tissue regeneration. *Journal of*  
6 *Clinical Periodontology* **25**, 475-481  
7  
8  
9

10 Zitzmann NU, Schärer P, Marinello CP, Schüpbach P & Berglundh T (2001) Alveolar  
11 ridge augmentation with Bio-Oss: a histologic study in humans. *International Journal*  
12 *of Periodontics Restorative Dentistry* **21**,288-95.  
13  
14  
15  
16  
17  
18  
19  
20  
21  
22  
23  
24  
25  
26  
27  
28  
29  
30  
31  
32  
33  
34  
35  
36  
37  
38  
39  
40  
41  
42  
43  
44  
45  
46  
47  
48  
49  
50  
51  
52  
53  
54  
55  
56  
57  
58  
59  
60

For Peer Review